

## The Role of Interventional Radiology in the Management of Obstetric and Gynaecological Haemorrhage

C. O'Brien<sup>1</sup>, G.M. Healy<sup>1</sup>, B.C. Anglim<sup>2</sup>, A. O'Brien<sup>1</sup>, J. Duignan<sup>1</sup>, A. Patel<sup>1</sup>, M. Cheung<sup>2</sup>, C. P. Cantwell<sup>1</sup>

1. Department of Radiology, St Vincent's University Hospital, Elm Park, Dublin 4
2. National Maternity Hospital, Dublin 2, Ireland

### Abstract

#### Aim

We will review our experience of emergent arterial embolization used to treat haemodynamically unstable patients with obstetric and gynaecological haemorrhage.

#### Methods

This is a retrospective study of patients with haemodynamically unstable obstetric and gynaecological haemorrhage treated with emergent arterial embolization from 2010 to 2015.

#### Results

22 patients (average age 41 (SD +/-9) years) had emergent arterial embolization. 63% had post-partum haemorrhage (PPH). 82% of cases were performed with conscious sedation and local anaesthesia. Embolization was technically successful in all cases. Embolization was clinically successful in 95% (21/22). In one case of PPH the patient represented six days later with recurrent bleeding and was treated with surgical suturing of the cervix. There were no complications or deaths.

#### Conclusion

Arterial embolization is a highly successful treatment of obstetric and gynaecological haemorrhage in unstable patients.

### Introduction

Obstetric and gynaecological haemorrhage are significant causes of morbidity and mortality. Cases of major obstetric haemorrhage are usually related to labour, while significant gynaecological haemorrhage is usually iatrogenic and related to procedures such as myomectomy, hysterectomy and cervical resection.

Postpartum haemorrhage (PPH) is defined as the loss of more than 500 ml of blood within the first 24 hours following childbirth. It can be minor (500-1,000ml estimated blood loss) or major (> 1,000ml). Major PPH is sub classified further as moderate (1,000-2,000ml), severe (> 2,000ml) or life threatening (>2,500ml /acute transfusion requirement of more than 5 units or treatment for coagulopathy)<sup>1</sup>. Secondary PPH occurs after 24 hours of the birth of the baby<sup>1</sup>. The incidence of PPH was 4.1% in Ireland in 2009 <sup>2</sup> with life- threatening haemorrhage occurring in 0.67% of deliveries<sup>3</sup>.

Primary PPH is the cause of 25% of maternal deaths<sup>4</sup>. The maternal death rate in Ireland is 6.5 per 100,000 maternities and there were two fatalities secondary to obstetric haemorrhage in the Republic of Ireland between 2011 and 2015 according to the confidential maternal death enquiry reports<sup>5</sup>.

The most common causes of PPH are uterine atony, uterine and lower genital tract laceration, invasive placentation, caesarean section, coagulation disorders, retained products of conception and/or fibroids. The main causes of secondary PPH include the causes of primary PPH (particularly retained placental fragment) in addition to endometritis and ruptured arterial pseudaneurysms<sup>6</sup>. There are recognised risk factors of PPH (including prior haemorrhage, high BMI etc) however, the majority of women have few or no risk factors, which makes PPH very challenging to predict. The rate of haemorrhage among low risk women with spontaneous vaginal deliveries is 0.4%, which compares to 1.6% in women with identified risk factors<sup>1,7</sup>.

Patients with PPH are initially resuscitated with aggressive intravenous crystalloid and blood transfusion. If unsuccessful further therapeutic options include uterine compression, uterotonic drugs, and correction of coagulopathy (traxenemic acid<sup>8</sup>, blood products). In patients with ongoing haemorrhage definitive treatment can sometimes only be achieved with arterial embolization or surgical hysterectomy<sup>9</sup>. In fact, PPH is the most common cause of emergency peripartum hysterectomy<sup>4</sup>. Uterine artery embolization (UAE) is an emerging treatment for post-partum haemorrhage and can successfully treat PPH in over 90 % of cases <sup>6,10,11</sup>potentially preventing the need for surgery.

Our centre is a University Hospital with an emergency department, inpatient gynaecology service and is a referral centre for a separate maternity hospital with over 9,000 live births per year. We aim to review our experience of arterial embolization used to treat haemodynamically unstable patients with obstetric and gynaecological haemorrhage.

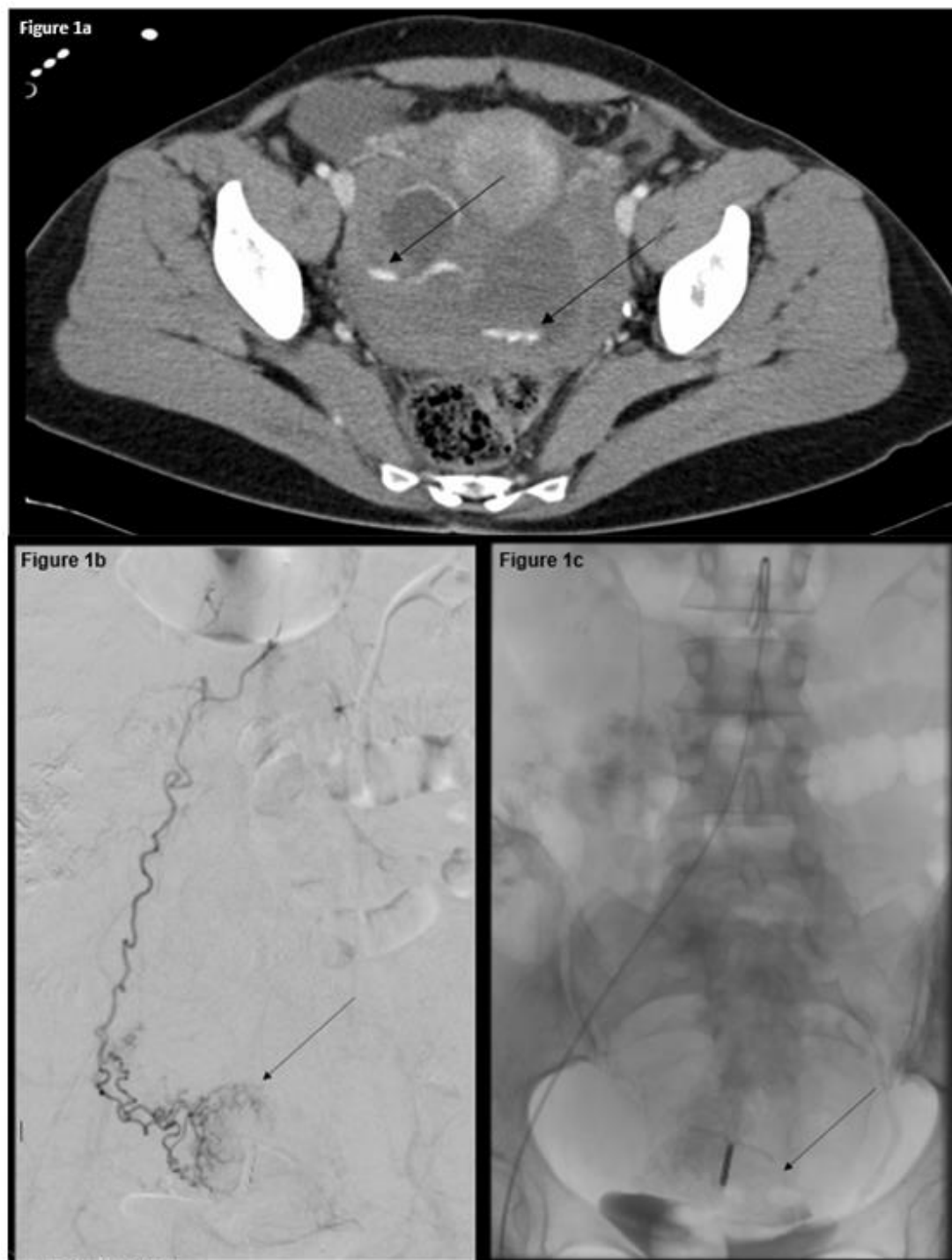
## Methods

Ethical approval was received for this study. The requirement for patient consent was waived as this is a retrospective study. The Radiology Information System (RIS) was searched for all emergency embolization procedures conducted for obstetric and gynaecological haemorrhage from 2010 to 2015 inclusive. Medical record review was conducted in the university hospital and the referring maternity hospital. Information was collected regarding indication, patient demographics, blood transfusion type and unit number, type of anaesthesia, procedure type, bleeding vessel location, embolic agent used, technical success, clinical success, length of hospital stay, complications and other procedures or treatments given after embolization.

In our institution patients with acute haemorrhage who are hemodynamically stable usually undergo a multiphasic CT study before proceeding to IR catheter angiography. The multiphasic CT is used for detection and localization of the source of haemorrhage. A CT protocol is used with non-contrast, early arterial, venous and delayed phases (at 120-180 seconds) after intravenous contrast administration. In cases where the patient is unstable, or where the source of the bleeding is known they may proceed directly to the interventional radiology suite for catheter angiogram, bypassing the CT scanner. Embolization for emergency haemorrhage is performed using common femoral artery access. In the case of occult or multiple sources of bleeding non-selective internal iliac and pelvic catheter arteriography is performed to delineate the arterial anatomy and identify the bleeding source. Selective catheterization was used to deliver embolic material for occlusion of the bleeding artery.

Technical success was defined as successful cannulation of the bleeding artery with occlusion of the artery using an embolic material. Clinical success was defined as a case in which the patient did not require transfusion or other treatment for ongoing blood loss after the embolization procedure.

**Figure 1.** 49-year-old female Jehovah Witness presented with spontaneous haemorrhage from a benign complex right ovarian cyst. Therapeutic options were limited as the clinical team were unable to administer blood products. (a) Axial contrast enhanced CT demonstrates extravasation of contrast (arrows) into the complex right ovary cyst which occupies the pelvis and is surrounded by old haemorrhage. (b) Digital subtraction angiogram (DSA) of the right ovarian artery with a hypervascular cyst seen in the right ovary (arrow). (c) Late angiographic image after right ovarian artery angiography demonstrates extravasated contrast in the pelvis from prior angiography external to the urinary bladder (arrow). This was successfully treated with unilateral ovarian artery embolization with metal coils.



## Results

A total of 22 patients underwent attempted embolization for obstetric and gynaecological haemorrhage. The average age of the women was 41 (SD  $\pm 9$ ) years. Fourteen (63%) patients had PPH (50% primary and 50% secondary), five cases (22%) were referred post hysterectomy (four abdominal hysterectomy and one transvaginal hysterectomy), one case was haemorrhage post large loop excision of the cervical transformation zone (LLETZ), one case of haemorrhagic ovarian cyst rupture and one case of a patient with metastatic cervical cancer. 85% (19/22) of cases were transferred

from the geographically separate maternity hospital and 15% (3/22) of cases were from the on-site inpatient gynaecology service.

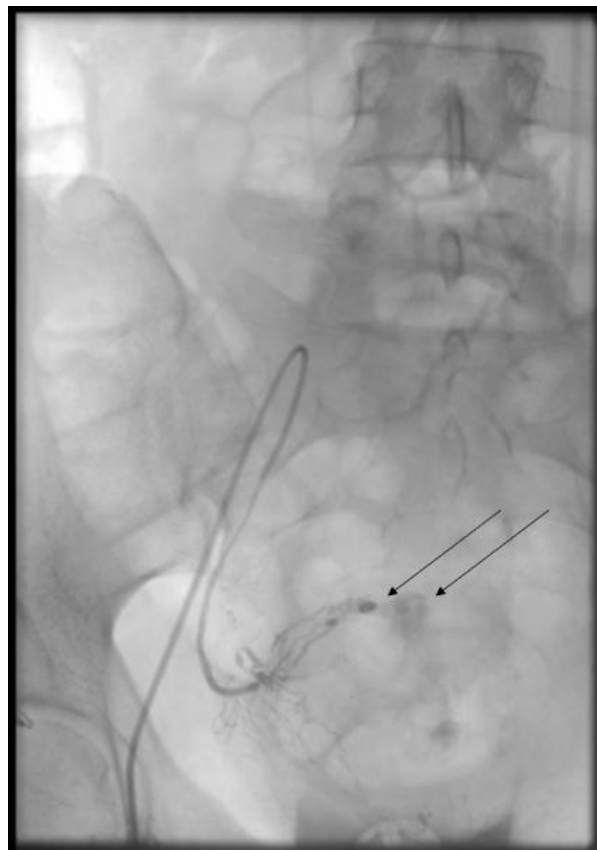
Multiphasic CT studies were performed prior to transfer to IR angiography suite in 23% (5/22) of cases with 80% (4/5) of these CT studies demonstrating active haemorrhage. On conventional catheter angiography active bleeding was seen in 45% (10/22) of cases and an abnormal vessel without bleeding ( i.e. pseudoaneurysm) was seen in 10% (2/22) of cases. In 45% (10/22) empiric embolization was performed in the regional arteries of suspected haemorrhage.

A variety of embolic agents were used; gelfoam (Pfizer, Michigan) prepared by the interventionist into a slurry or torpedoes in 15/22 cases. In 2/15 cases gelfoam was combined with a second embolic material: in one case metal coils (COOK Medical, Bloomington, Indiana) and in a second case tris-acryl gelatin microspheres (Embospheres, Merit medical, South Jordan, Utah). In six cases, metal coils alone were used and in one case tris-acryl gelatin microspheres were used alone.

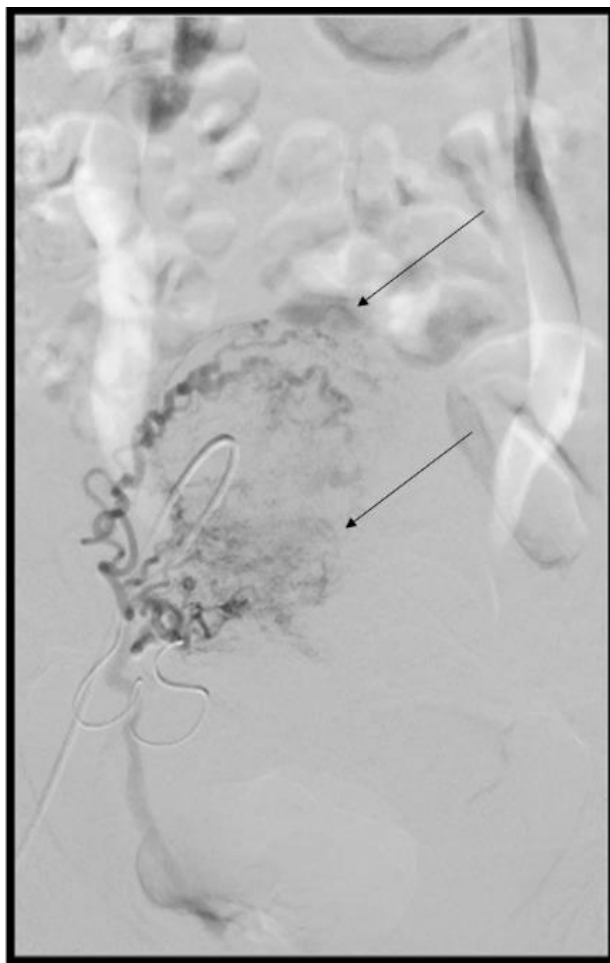
All 22 cases were a technical success. In all of the women who had external bleeding (20/22), the external bleeding resolved immediately. In all cases of severe initial bleeding, haemodynamic stability and immediate correction of the coagulopathy was obtained. The clinical success rate was 95% (21/22). The one case which was not clinically successful was that of a 38-year-old woman with primary PPH. The case was a technical success with occlusion of the bleeding vessel during catheter angiography. The patient represented six days later with recurrent per vaginal haemorrhage and underwent examination under anaesthesia and cervical suturing. There were no serious complications or deaths. No patient in our cohort had a hysterectomy for PPH.

Eighty two percent (19/22) of the cases were performed under conscious sedation and three cases (14%) required a general anaesthetic. Three patients (14%) were admitted to ICU after the procedure with the remaining 19 being treated with ward level care. Thirteen (59%) were discharged home or back to their maternity centre on day one and eighteen (82%) of the twenty two patients were discharged home within three days. No procedure related complications were reported in our cohort.

**Figure 2. 33-year-old female with secondary PPH after vaginal bleeding 17 days after caesarean section delivery and subtotal abdominal hysterectomy for a cervical pregnancy. (a) Conventional angiographic image of a selective right uterine artery demonstrates active haemorrhage (arrow) from cervical artery branch (arrowhead). This was successfully treated with gelfoam embolization.**



**Figure 3.** 32-year-old female with secondary PPH 28 days after caesarean section with retained products of conception. (a) DSA image of a selective right uterine artery demonstrates active haemorrhage (arrow) from tortuous uterine artery branch. This was successfully treated with bilateral uterine artery embolization with 700 $\mu$ m beads.



## Discussion

PPH and gynaecological haemorrhage are potentially life-threatening conditions which need multidisciplinary management by obstetricians and gynaecologists, anaesthesiologists, haematologists and interventional radiologists. Our study demonstrates that arterial embolization is a highly effective management option for those patients who fail conservative management strategies. It may avoid the need for internal iliac ligation or hysterectomy and it achieves haemostasis in the majority of women, even after failed surgery<sup>6</sup>. Patients treated with uterine and ovarian embolization can potentially preserve their fertility and there have been reports of women successfully given birth subsequently<sup>12</sup>.

During the six years of our study, only 22 cases of obstetric and gynaecological haemorrhage were referred to our department. This is a low volume of cases, however most Interventional Radiology centres will nonetheless have significant experience with UAE. In fact, the majority of UAE procedures performed in Irish hospitals are elective procedures. Elective UAE has emerged as a minimally invasive alternative to surgical management of fibroids in women who fail conservative medical management with reported clinical success at 5 years in 93% of cases<sup>13,14</sup>.

When performing an emergency UAE, we will look to identify a target lesion for embolization on CT or conventional angiography. The most obvious target is an actively bleeding artery, however we will also interrogate the vessels look for an acute vascular finding, such as pseudoaneurysm, arteriovenous malformation or irregular / truncated artery. More than half of patients in our series did not demonstrate an acute vascular finding on angiography and this is concordant with the results from prior case series<sup>6</sup>. Haemorrhage is usually intermittent and associated with arterial spasm limiting the ability of conventional angiography (performed as a 'snap shot' over 5-10 seconds) to detect active haemorrhage. In the absence of an actively bleeding vessel or abnormal artery being identified, an empiric embolization of the regional arterial anatomy (e.g. bilateral uterine arteries) with a temporary embolic material such

as gelfoam is an accepted and successful approach. Our clinical success rate of 95% as reported in this study is in line with international studies<sup>6</sup>.

Complications of pelvic artery embolization are rare. Complications include muscle pain, neurologic damage, bladder necrosis and vesicovaginal fistula. These complications are more likely to be found in elderly women, patients with pelvic neoplasms or who had previously been treated with radiotherapy<sup>6</sup>. None of the patients in our cohort reported any of these complications.

According to the WHO Multicounty Survey on Maternal and Newborn Health, the rate of emergency peripartum hysterectomy has halved in the last two decades due to increased use of modern treatments including UAE<sup>15</sup>. Conservative treatment remains the cornerstone of management for these patients and it is widely available in the community setting, for example, in sub-Saharan Africa, Tranexamic has been shown to reduce PPH by up to 30%<sup>16</sup>. The majority of bleeding episodes will resolve without the need for advanced interventions, however there will always be a group of cases will fail to resolve conservative measures and UAE is an excellent minimally invasive treatment for these women.

Arterial embolization is a highly successful treatment of obstetric and gynaecological haemorrhage in unstable patients.

### Declaration of Conflicts of Interest

This work has not been presented before. The authors declare no conflict of interest.

### Corresponding Author

Dr. Cormac O'Brien,  
Radiology Department  
St. Vincent's University Hospital  
Elm Park  
Dublin 4  
Ireland  
Tel: +35312214000  
Email: cormacobrien@svuh.ie

### References

1. Scotland NHS U. 10th Annual Report of the Scottish Confidential Audit of Severe Maternal Morbidity; reducing avoidable harm. Healthcare Improvement Scotland. 2012:14-22.
2. JE L, BM B, D D, RA G. Increasing trends in atonic postpartum haemorrhage in Ireland: an 11-year population-based cohort study. *BJOG An Int J Obstet Gynaecol*. 119(3):306-314. doi:10.1111/j.1471-0528.2011.03198.x.
3. Mavrides E, Allard DS, Chandrachan DE, et al. Postpartum Haemorrhage, Prevention and Management (Green-top Guideline No. 52). 2016. <https://www.rcog.org.uk/en/guidelines-research-services/guidelines/gtg52/>.
4. WR S, Blum J, JP V, JP S, AM G, Winikoff B. Postpartum haemorrhage management, risks, and maternal outcomes: findings from the World Health Organization Multicountry Survey on Maternal and Newborn Health. *BJOG An Int J Obstet Gynaecol*. 2014;121(s1):5-13. doi:10.1111/1471-0528.12636.
5. MF O'Hare, E Manning, P Corcoran RG. *Confidential Maternal Death Enquiry in Ireland Report for 2013 - 2015*; 2017. doi:ISSN 2009-7298.
6. Soyer P, Dohan A, Dautry R, et al. Transcatheter Arterial Embolization for Postpartum Hemorrhage: Indications, Technique, Results, and Complications. *Cardiovasc Intervent Radiol*. 2015;38(5):1068-1081. doi:10.1007/s00270-015-1054-y.
7. Briley A, PT S, Tydeman G, et al. Reporting errors, incidence and risk factors for postpartum haemorrhage and progression to severe PPH: a prospective observational study. *BJOG An Int J Obstet Gynaecol*. 2014;121(7):876-888. doi:10.1111/1471-0528.12588.
8. Shakur H, Roberts I, Fawole B, et al. Effect of early tranexamic acid administration on mortality, hysterectomy, and other morbidities in women with post-partum haemorrhage (WOMAN): an international, randomised, double-blind, placebo-controlled trial. *Lancet*. 2017;389(10084):2105-2116. doi:10.1016/S0140-6736(17)30638-4.

9. Liu Z, Wang Y, Yan J, et al. Uterine artery embolization versus hysterectomy in the treatment of refractory postpartum hemorrhage: a systematic review and meta-analysis. *J Matern Neonatal Med.* 2018;1-13. doi:10.1080/14767058.2018.1497599.
10. Pelage J-P, Soyer P, Repiquet D, et al. Secondary Postpartum Hemorrhage: Treatment with Selective Arterial Embolization. *Radiology.* 1999;212(2):385-389. doi:10.1148/radiology.212.2.r99jl05385.
11. Pelage JP, Le Dref O, Mateo J, et al. Life-threatening primary postpartum hemorrhage: treatment with emergency selective arterial embolization. *Radiology.* 1998;208(2):359-362. doi:10.1148/radiology.208.2.9680559.
12. Lee HY, Shin JH, Kim J, et al. Primary Postpartum Hemorrhage: Outcome of Pelvic Arterial Embolization in 251 Patients at a Single Institution. *Radiology.* 2012;264(3):903-909. doi:10.1148/radiol.12111383.
13. Liang E, Brown B, Kirsop R, Stewart P, Stuart A. Efficacy of uterine artery embolisation for treatment of symptomatic fibroids and adenomyosis – An interim report on an Australian experience. *Aust New Zeal J Obstet Gynaecol.* 2012;52(2):106-112. doi:10.1111/j.1479-828X.2011.01399.x.
14. Katz MD, Sugay SB, Walker DK, Palmer SL, Marx MV. Beyond Hemostasis: Spectrum of Gynecologic and Obstetric Indications for Transcatheter Embolization. *RadioGraphics.* 2012;32(6):1713-1731. doi:10.1148/rg.326125524.
15. World Health Organization T. *WHO Recommendations on Prevention and Treatment of Postpartum Haemorrhage and the WOMAN Trial.*; 2012. [www.who.int/reproductivehealth/publications/maternal\\_perinatal\\_health/9789241548502/en/](http://www.who.int/reproductivehealth/publications/maternal_perinatal_health/9789241548502/en/).
16. McClure EM, Jones B, Rouse DJ, et al. Tranexamic Acid to Reduce Postpartum Hemorrhage: A MANDATE Systematic Review and Analyses of Impact on Maternal Mortality. *Amer J Perinatol.* 2015;32(5):469-474. doi:10.1055/s-0034-1390347.