

Digitalis Poisoning after Accidental Foxglove Ingestion

T. Popoola, E. Umana, J. Binchy

Emergency Department, University Hospital Galway, Ireland.

Abstract

Presentation

A 22-year-old man presented to the Emergency Department (ED) with a history of persistent gastrointestinal symptoms, drowsiness, light-headedness, blurred vision and numbness of the lips for a day after accidentally ingesting foxglove.

Diagnosis

Serial electrocardiography demonstrated significant changes ranging from sinus bradycardia to varying degrees of heart block with ST segment depression and T wave inversion in the inferior and anterolateral leads. A diagnosis of probable digitalis (cardiac glycoside) poisoning was made.

Treatment

After initial emergency medicine approach and assessment; his treatment included intravenous atropine, antiemetic, activated charcoal and Digibind with referral to the cardiology team for observation.

Conclusion

A high index of suspicion for digitalis toxicity in a symptomatic patient with unknown plant ingestion is crucial in the ED. This case also highlights the emergency management approach of such patients with atropine and activated charcoal.

Introduction

Digitalis poisoning from the therapeutic use of herbal cardiac glycosides (CG) continues to be a source of toxicity today¹. CG are found in a diverse group of plants, the commonest being, foxglove (*Digitalis purpurea*). Toxicity may occur after consuming juice or teas brewed from plant parts or after consuming leaves, flowers, or seeds from such plants¹.

Case Report

A 22-year old man presented to the Emergency Department (ED) with a history of persistent vomiting, abdominal discomfort, drowsiness, light-headedness, blurred vision and numbness of the lips for a day. He had blended 2 big leaves of an unknown plant growing wild in his garden with apple, cucumber and lettuce to make a "herbal juice". He became unwell about 2 hours after ingestion and later presented to the ED when his symptoms failed to resolve. Collateral information provided by his parents identified the ingested plant was foxglove. He had no medical background of note and had no regular medications or allergies.

On examination he was stable; orientated; conscious and had a bradycardia of 40 beats/minute. All other vital signs were within normal limits (BP=117/58, RR=16, SaO₂=97%, T=36.5). His general examination was normal.

Serial ECGs revealed significant cardiac arrhythmias ranging from sinus bradycardia to 1st degree heart block, 2nd degree heart block (Mobitz type II) and complete heart block with ST depression and T wave inversion in inferior and anterolateral leads (Figures 1 and 2). Serum digoxin level was normal (0.6 µg/L). Renal profile showed acute kidney injury (urea: 9.0mmol/l, creatinine: 125µmol/l) and mild hyperkalaemia (5.3mmol/L). There was leucocytosis (19.5 x 10⁹/l) with neutrophilia (17.5 x 10⁹/l). He had a normal chest radiograph. A diagnosis of probable digitalis poisoning was made.




Figure 1: ECG showing complete heart block with ST depression and T wave inversion in inferior and anterolateral leads.

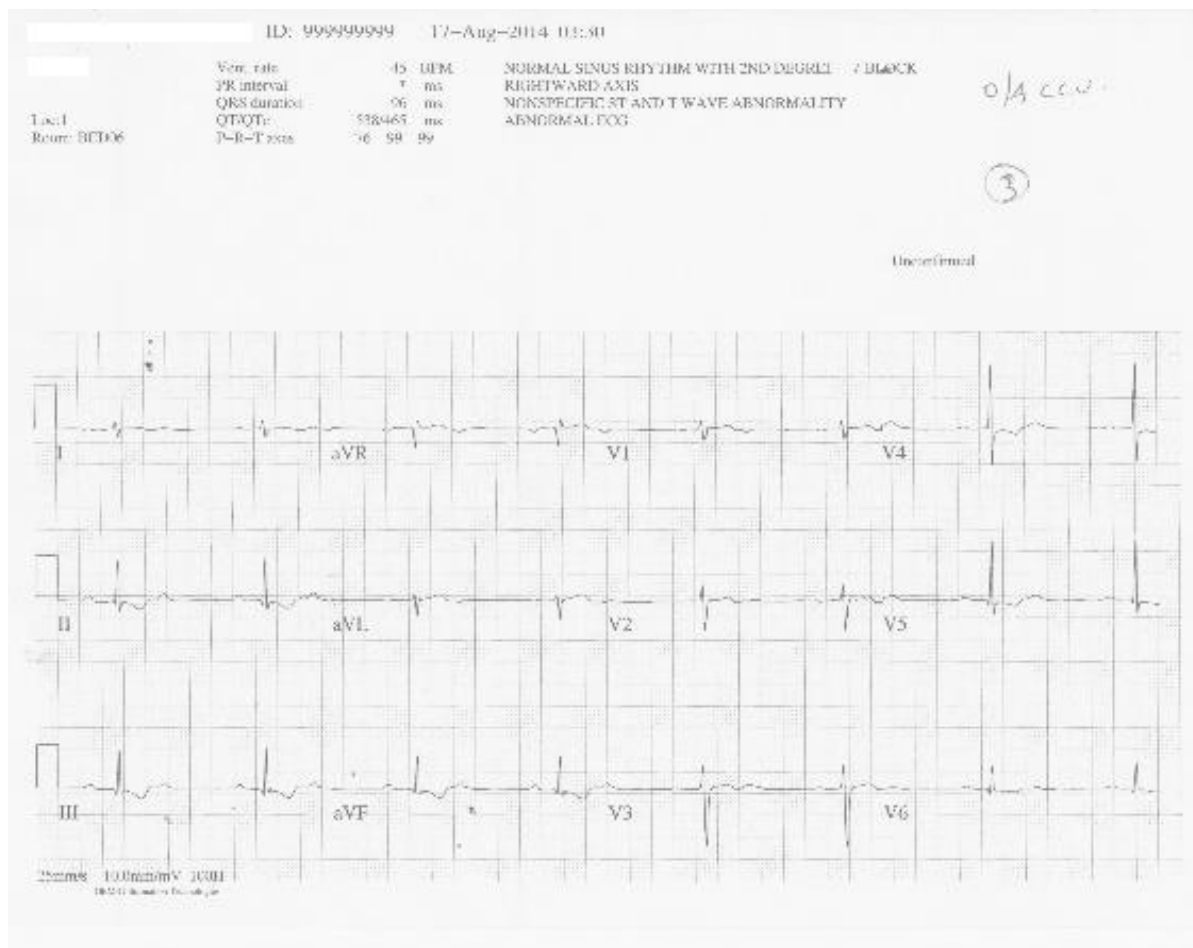


Figure 2: ECG showing 2nd degree heart block (Mobitz type II) with ST depression and T wave inversion in inferior and anterolateral leads.

He was managed according to the Emergency Medicine ABC approach. He was given intravenous fluid and an antiemetic. Atropine 0.6mg intravenously was given to manage the bradycardia with good response. Activated charcoal was administered following Toxbase (an online poisons information database) recommendation. Three further doses of atropine were given because of labile heart rate. A cardiology review was requested, and he was transferred to coronary care unit (CCU), where he had a dose of Digibind (digoxin-specific antibody, an antidote for digoxin overdose) and commenced on telemetry. There were further changes in his ECG but these normalised overtime. His serum digoxin levels progressively decreased to 0.3 µg/L. He was discharged home after ten days on admission with resolution of laboratory parameters.

Discussion

CGs are organic compounds containing glycosides (sugar) that act on the contractile force of the cardiac muscle by inhibiting the sodium–potassium–adenosinetriphosphatase enzyme². Arrhythmias are the main cardiac manifestation of CG poisoning, ranging from bradycardias to fatal tachyarrhythmias³. Patients presenting with acute ingestion could also develop gastrointestinal (nausea, vomiting and abdominal pain) and neurological (confusion and weakness) symptoms.

The diagnosis of CG toxicity is based on history, clinical manifestations and ECG findings with confirmation of serum digoxin levels ⁴. Due to the cross-reactivity of the digoxin immunoassay, the quantitative value does not correlate with the degree of toxicity from exposure to plant-based CG and may even be undetectable. Potassium derangement is the most common electrolyte abnormality with hyperkalaemia being a marker of acute CG toxicity and a predictor of mortality ³.

The management is generally supportive in addition to Digibind. Digibind use should be guided by a robust history and clinical manifestations ³. Activated charcoal can be considered in the management of patients with CG ingestion as it blocks the absorption and improves elimination of CG ³. Activated charcoal can be given as single or multiple doses in patients who are symptomatic post plant CG ingestions ⁵. Although TOXBASE recommends its use beyond the hour mark there are no randomised control trials establishing its use ⁵. Mitchell et al reported successful use of multiple doses of activated charcoal in the treatment of plant CG ingestion ⁶. Symptomatic patients with CG poisoning will require admission to CCU for close monitoring until symptoms resolution. Emergency physicians should consider CG poisoning in patients presenting with gastrointestinal symptoms and cardiac arrhythmias following ingestion of an unidentified plant and despite low digoxin levels.

Declaration of Conflicts of Interest:

There is no conflict of interest.

Corresponding Author:

Dr Taiwo Olukunle Popoola
Emergency Department
University Hospital Galway
Ireland.
Email: kunlepopy2k@yahoo.com

References:

1. Kapitanayan R, Su M. Cardiac glycoside plant poisoning medication. Medscape 2017. Available from <https://emedicine.medscape.com/article/816781-overview>.
2. Janssen RM, Berg M, Ovakim DH. Two cases of cardiac glycoside poisoning from accidental foxglove ingestion. CMAJ. 2016;188(10):747–750. doi:10.1503/cmaj.150676.
3. Levine MD, O’Conor A. Digitalis (cardiac glycoside) poisoning. In: Basow DS, ed. Up-to-Date [database on the Internet]. Waltham (MA): UpToDate; 2020 [cited 24 April 2020]. Available from: <http://www.uptodate.com>.
4. Smith TW, Antman EM, Friedman PL, et al. Digitalis glycosides: mechanisms and manifestations of toxicity. Part I. Prog Cardiovasc Dis 1984;26:413-58.
5. TOXBASE. Digitalis purpurea (Foxglove), 02/2020. <http://www.toxbase.org> (accessed 04/2020).
6. Mitchell A. Bitter pill to swallow: a case of accidental poisoning with digitalis purpurea. BMJ Case Reports 2010; doi:10.1136/bcr.01.2010.2633.