

## **Endoscopic Ear Surgery (EES): A New Vista in Otology**

I.J. Keogh<sup>1,2</sup>, R. Fahy<sup>1,2</sup>, S. Garry<sup>1,2</sup>, E. Fahy<sup>1,2</sup>, M. Corbett<sup>1,2</sup>

1. Academic dept of otorhinolaryngology, National University of Ireland, Galway, Ireland.
2. Department of Otorhinolaryngology, Head and Neck Surgery, University Hospital Galway.

### **Abstract**

#### **Aim**

Endoscopic Ear Surgery (EES) is increasingly being used both as an adjunct to surgery with a microscope and as a standalone procedure. Technological advancements such as high definition cameras and small diameter fibreoptics, allow superior quality images with a wider field of view. As with all new surgical procedures, there are advantages and disadvantages. We aim to share our experience of EES.

#### **Methods**

Following institutional ethical approval. We undertook a retrospective review of a consecutive cohort of patients (children and adults) who, between 2008-2019, underwent otologic surgery in our centre. Data was collected using theatre records and clinical notes.

#### **Results**

2,062 procedures were included, 1,703 with binocular microscope and 359 EES procedures. The first EES procedures in our centre were carried out in 2013. Numbers and complexity have increased year on year; 2013 (3), 2019 (118). All EES were day case procedures and there were no major complications associated with the introduction of EES. EES procedures ranged from examination under anaesthesia to tympanoplasty, middle ear exploration and ossicular chain reconstruction.

#### **Conclusion**

EES uses the ear canal as an access port to the middle ear. With practice, more complex, totally endoscopic otologic surgeries may be carried out, targeting dysventilation, the fundamental cause of chronic ear disease and cholesteatoma. EES has proven to be a safe and valuable otologic procedure, facilitating high definition views of areas otherwise unseen.

## **Introduction**

The middle ear is a complex structure wrapped in dense bone and surrounded by very important structures <sup>(1)</sup>. The brain, carotid artery, jugular vein and facial nerve are intimately associated and only millimetres away (figure 1). In the pre antibiotic era chronic infective and inflammatory diseases of the middle ear or mastoid frequently spread to the meninges and brain <sup>(2)</sup>. Otogenic intracranial complications were associated with mortality rates as high as 80% <sup>(3)</sup>. Acute otitis media and otitis media with effusion continue to be among the most common conditions affecting children worldwide <sup>(4)</sup>.

The advent of antibiotics has significantly reduced the incidence of complications secondary to acute and chronic otologic disease <sup>(5)</sup>. The introduction of the binocular operating microscope in 1951 and the development of the high-speed drill were landmark events in modern otologic surgery <sup>(6)</sup>. Better, safer visualisation and more precise removal of chronic disease have resulted in significant improvements in surgical outcomes <sup>(7)</sup>.

Until recently there has been little innovation or change in the surgical approach to chronic ear disease. However, a small but increasing number of otologists have championed the practice and development of minimally invasive ear surgery <sup>(8,9)</sup>. Using the external auditory canal as the access port and the Hopkins rod endoscope, a new vista has evolved, Endoscopic Ear Surgery (EES). Using the rigid endoscope as a primary tool for ear surgery allows the surgeon to target the birthplace of chronic ear disease and better manage the underlying cause, dysventilation (figure 2). When the complete surgery is performed endoscopically it is called Totally Endoscopic Ear Surgery (TEES).

Recent optical advancements such as small (2-3mm) diameter fibreoptics and HD monitors bring the otologist into a magnified world of superior images. (Figure 3)

Otoendoscopic procedures can range from tympanostomy tube insertion to middle ear exploration. EES is challenging with a steep learning curve, like all new surgical techniques there are advantages and disadvantages. Recently surgeries have been performed using the endoscope in the management of cerebellopontine angle tumours <sup>(10)</sup>. Literature has shown that endoscopic approaches are comparable to traditional microscopic surgeries <sup>(11,12)</sup>. The aim of this study is to share our experiences introducing EES into our otology practice.

## **Methods**

Local institutional ethical approval was obtained. We undertook a retrospective review of a consecutive cohort of patients, children and adults, who underwent otologic surgery in our centre. Cases were included from 2009 to 2019 under the care of the senior author (I.K). Data was compiled using theatre records and clinical notes. We examined how EES has changed our practice over the past 10 years. Descriptive data analysis was conducted using Microsoft® Excel (Microsoft® Corp., Redmond, WA).

## Results

Two thousand and sixty-two Otologic surgeries were carried out over a 10-year period under the care of a single consultant surgeon. Patients ages ranged from 9 months to 86 years old. Microscope was used for 1703 otologic cases. Three hundred and fifty-nine EES procedures were carried out. Our first EES procedures were carried out in 2013, three cases of otoendoscopy using a 4mm rigid Hopkins rod endoscope and standard middle ear instruments.

All EES were day case procedures and there were no complications associated with the introduction. The number of EES at our centre has risen on an annual basis since its introduction with 95 cases completed using otoendoscopy in 2018 and 118 cases in 2019. There has been an increase in case complexity and variation year on year with no increase in complications or operating times. In 2019 approximately 80% of otologic surgeries were carried out by TEES alone. A significant advantage has been the ability to perform all these surgeries as day cases. Many of these patients would have required overnight admission, particularly if there was a post auricular or endaural approach. Apart from the obvious financial advantages, patients do not require head bandage dressings, wound management, and importantly have no scars. Procedures varied from assessment and photography using the endoscope to endoscopic middle ear exploration and mastoid debridement (Table 1).

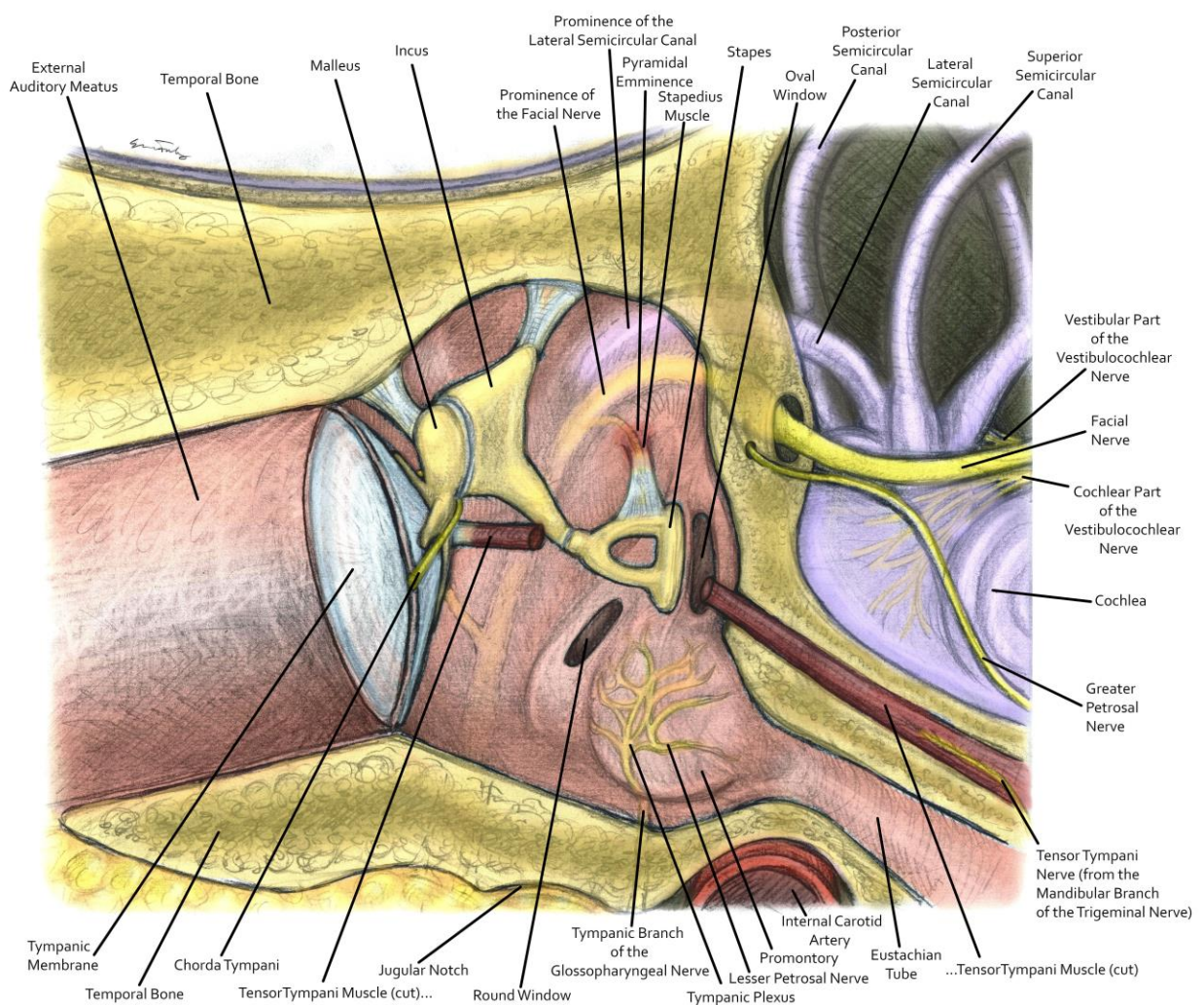


Figure 1: Relations of the middle ear.

Table 1. Endoscopic Ear Surgery by Procedure.

Endoscopic Ear Surgery by Procedure	
Otoendoscopy	135
Ventilation tube insertion	97
Middle ear exploration +/- Ossicular Chain Reconstruction	19
Debulk Attic/cholesteatoma	72
Transcanal tragal cartilage tympanoplasty	28
Mastoid debridement / excision of cholesteatoma	8

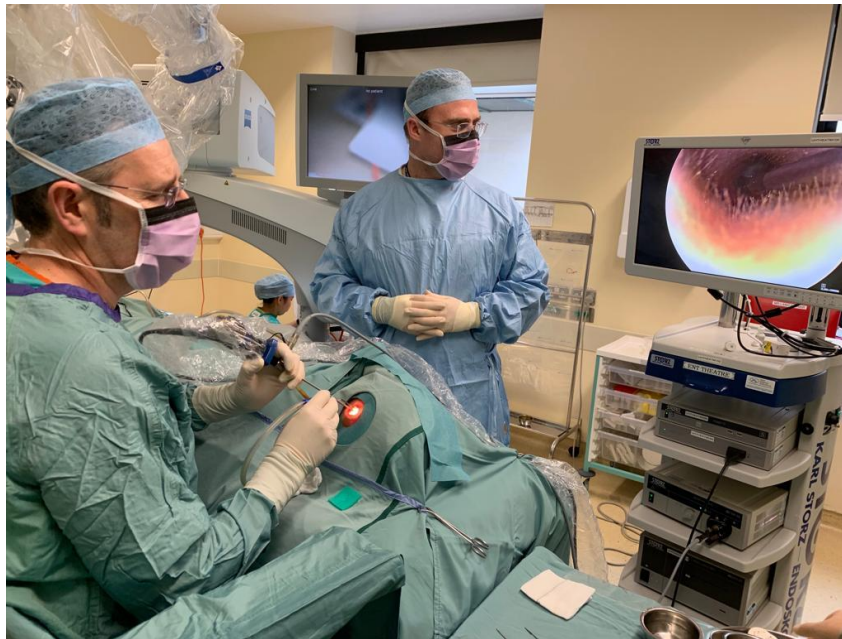

Figure 2: Endoscopic Ear Surgery set up.

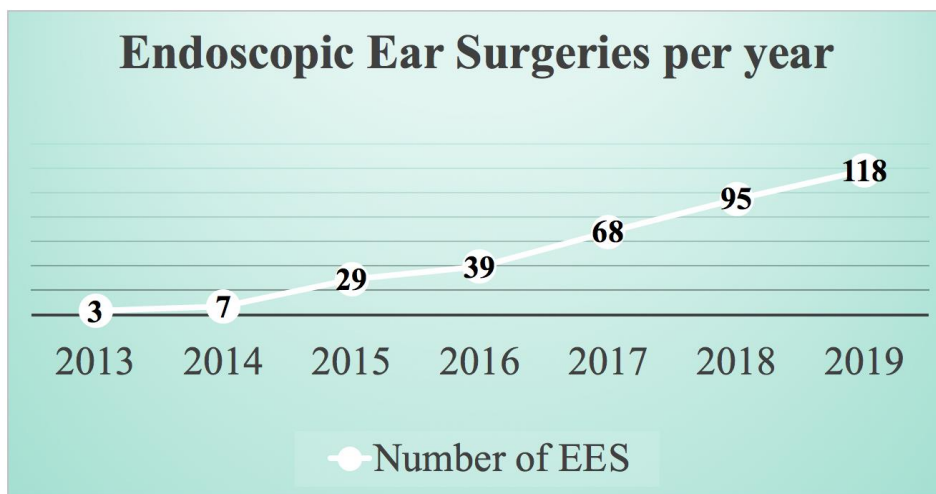


Figure 3: Annual Endoscopic Ear Surgeries.

## Discussion

Otoendoscopy is a useful, minimally invasive diagnostic tool. Excellent visualization is afforded of diseased tympanic membranes, mastoid cavities and middle ears. Procedures are less invasive than traditional microscopic surgery. High quality images can be captured, printed and recorded. This gives an objective visual aid to the surgeon for future operative planning. Furthermore, these images can be used for comparative purposes following therapeutic interventions or to monitor disease progression. Images taken at time of surgery can later be shown to the patient to facilitate better patient understanding. Microscopic ear surgery relies very much on the line of sight. The narrowest segment of the ear canal and bony “overhangs” limit visualisation. Traditionally this limitation resulted in the necessity of a parallel port through the mastoid bone and a post auricular approach. This allowed parallel access to the attic and facial recess. Fundamental optical limitations have not improved until recently.

The main advantage of EES over microscopic ear surgery is the image quality produced. Not only is the endoscope capable of getting closer to structures within the ear and providing a higher quality image. The endoscope has a wider angle of view and is able to visualize areas of the middle ear otherwise unseen under a microscope. This allows a greater field of vision and allows the user to ‘look around corners’ using angled lenses. The detail seen using the endoscope is particularly useful in locating residual cholesteatoma when compared to a microscope <sup>(13)</sup>.

EES offers non-invasive methods that reduce the need for a post auricular approach to the middle ear. In the case of cholesteatoma removal a post-auricular mastoidectomy via microscope is often necessary to provide adequate visualization on the middle ear and to evaluate disease. Due to the non-invasive approach afforded by EES patients may have a shorter recovery time and may avoid external scars <sup>(14)</sup>.

There is a learning curve associated with EES. Endoscopic dissection requires a single-handed approach as the surgeon is also required to hold the endoscope. Depth perception can be more challenging as microscopic surgery allows binocular vision. Microscopes are more easily available and accessible to trainees so can be easier for practicing and developing skills. Care must be taken when performing EES as imprecise movements can result in trauma to the ossicular chain and external auditory canal or thermal injury from the light source. Overall complication rates are comparable between microscopic and endoscopic surgery <sup>(15,16)</sup>. Once external canal diameter is suitable to admit an endoscope and instrumentation there is no absolute contraindication to EES.

A variety of specialized endoscopic otology instrument sets are now available. Finer instruments with a range of angled “heads” and some with suction ports improve technical challenges. Zero-degree 3mm (11cm) Hopkins rod endoscopes are now standard for EES. Minor ergonomic changes need to be made in theatre, with the huge advantage that EES forces the surgeon into a heads up and straight back position, potentially avoiding the frequent neck and back musculoskeletal issues suffered by many otologists, who are often “bent under” a microscope for hours at a time.

Not only is it useful for the surgeon to have the ability to compare 'before and after' images of the tympanic membrane and other structures, it is also a valuable learning resource for trainee's and medical students alike. With more procedures and an increased endoscopic caseload, trainees can progress with index procedures and can be directed and supervised safely using the monitor. In an outpatient setting, having the opportunity to review images of a previously diseased ear and to then compare it to a current situation is an effective tool both clinically and for teaching purposes. Anecdotally, trainee registrars and more junior staff alike find it to be a useful resource and aid in picking up on subtle findings on ear examination that may otherwise go unnoticed.

The use of EES is increasing. Otoendoscopy provides high quality images with a wide angled view for optimal visualization of anatomy of the ear. Its use exclusively or as an adjunct in procedures reduces the need for invasive techniques and improves patient recovery times. With better understanding of the equipment more extensive surgeries can be performed using a totally endoscopic approach. This minimally invasive technique has the potential to improve patient care and significantly reduce the need for overnight admissions. EES has proven to be a valuable safe, patient focussed tool in an ENT surgeon's arsenal giving an eye to areas otherwise unseen.

**Declaration of Conflicts of Interest:**

The authors report no conflicts of interest in this work.

**Corresponding Author:**

Mel Corbett

Orchid ID: 0000-0001-5320-1015

E-mail: [melcorbett@rcsi.ie](mailto:melcorbett@rcsi.ie)

**References:**

1. Luers J, Hüttenbrink K. Surgical anatomy and pathology of the middle ear. *Journal of Anatomy*. 2015;228(2):338-353.
2. Hafidh M, Keogh I, Walsh R, Walsh M, Rawluk D. Otogenic intracranial complications. A 7-year retrospective review. *American Journal of Otolaryngology*. 2006;27(6):390-395.
3. Palva T, Virtanen H, Makinen J. Acute and latent mastoiditis in children. *J Laryngol Otol*. 1985;99:127-136.
4. Liese J, Silfverdal S, Giaquinto C, Carmona A, Larcombe J, Garcia-Sicilia J et al. Incidence and clinical presentation of acute otitis media in children aged <6 years in European medical practices – ERRATUM. *Epidemiology and Infection*. 2014;143(7):1566-1566.
5. Myers E, Ballantine H. The management of otogenic brain abscesses. *The Laryngoscope*. 1965;75(2):273-288.
6. Mudry A. The history of the microscope for use in ear surgery. *American journal of Otolaryngology*. 2000;21(6):877-86.
7. Gibson W. The Operating Microscope and the Development of Ear Surgery. *Journal of the Royal Society of Medicine*. 1980;73(1):53-55.

8. Tarabichi M. Endoscopic Middle Ear Surgery. *Annals of Otolaryngology, Rhinology & Laryngology*. 1999;108(1):39-46.
9. IWGEES – International Working Group on Endoscopic Ear Surgery [Internet]. [iwgees.org](https://iwgees.org/). 2020 [cited 29 February 2020]. Available from: <https://iwgees.org/>
10. Shi-ming Y, Li-Mei Y, Yi-hui Z, Li-Ming Y, Fei J, Wei-yan Y et al. Endoscope Assisted Cerebellopontine Angle Surgery. *Journal of Otolaryngology*. 2009;4(1):44-49.
11. Hsu Y, Kuo C, Huang T. A retrospective comparative study of endoscopic and microscopic Tympanoplasty. *Journal of Otolaryngology - Head & Neck Surgery*. 2018;47(1).
12. Kozin E, Gulati S, Kaplan A, Lehmann A, Remenschneider A, Landegger L et al. Systematic review of outcomes following observational and operative endoscopic middle ear surgery. *The Laryngoscope*. 2014;125(5):1205-1214.
13. Ayache S, Tramier B, Strunski V. Otoendoscopy in cholesteatoma surgery of the middle ear: what benefits can be expected?. *Otology and Neurotology*. 2008;29(8).
14. Ayache S, Tramier B, Strunski V. Otoendoscopy in cholesteatoma surgery of the middle ear: what benefits can be expected?. *Otology and Neurotology*. 2008;29(8).
15. Kozin E, Lehmann A, Carter M, Hight E, Cohen M, Nakajima H et al. Thermal effects of endoscopy in a human temporal bone model: Implications for endoscopic ear surgery. *The Laryngoscope*. 2014;124(8):E332-E339.
16. Nomura K, Oshima H, Yamauchi D, Hidaka H, Kawase T, Katori Y. Ototoxic Effect of Ultrastop Antifog Solution Applied to the Guinea Pig Middle Ear. *Otolaryngology-Head and Neck Surgery*. 2014;151(5):840-844.