

Pericardial Fat Necrosis

M. Alsharif¹, R. Armstrong², N. Sheehy¹, D. Byrne¹

1. Department of Radiology, St. James's hospital, Dublin, Ireland.
2. Department of Cardiology, St. James's hospital, Dublin, Ireland.

Abstract

Presentation

We present a case of a gentleman who attended the emergency department with acute left sided chest pain, which was sharp in nature without any other associated symptoms. ECG did not demonstrate any evidence of infarction or ischemia and troponin was negative.

Diagnosis

CT coronary angiography (CTCA) was performed which did not show any evidence of coronary artery disease. However, stranding in the epicardial fat adjacent to the left ventricle and a left pleural effusion, were noted which can be seen in the setting of acute pericardial fat necrosis.

Treatment

The patient was managed conservatively and discharged.

Conclusion

Pericardial fat necrosis is an infrequent self-limiting condition, which manifests with acute chest pain.

Introduction

In 1957, Jackson, Clagett, and McDonald described three cases of pericardial fat necrosis, which is a rare entity¹. In line with recent European guidelines for the investigation of patients with acute chest pain, negative troponin, and absence of ischemic change on ECG, increasingly CTCAs are being performed to assess for underlying coronary artery disease, to reduce the need for invasive angiography in patients with low to intermediate pre-test probability².

Case Report

A 48-year-old male with no underlying medical conditions attended the emergency department with history of sudden onset of left sided chest pain. The pain was sharp in nature and was aggravated by movement with no relieving factors reported. The pain did not radiate to the jaw or left upper limb and the patient denied associated dyspnea, nausea, or diaphoresis.

The patient had a strong family history of ischemic heart disease and had stopped smoking one year prior to presentation reporting a 1-pack year history.

On examination, the patient was conscious and alert. Vital signs and cardiovascular examination were normal. ECG did not demonstrate any signs of ischemia and serial troponins were negative.

In light of the patient's family history of ischemic heart disease and atypical pain, CTCA was performed to exclude underlying coronary artery disease.

CTCA was acquired utilizing prospective gated technique following intravenous contrast administration and showed normal origin, course, and termination of coronary arteries without any CT evidence of coronary artery atherosclerosis. However, stranding was noted in the epicardial fat at the anterior aspect of the left anterior descending artery (LAD). The LAD was closely evaluated for evidence of underlying dissection which can also be associated with epicardial fat stranding³ but was noted to opacify normally without any underlying luminal irregularity or dissection flap. A small ipsilateral pleural effusion was also noted.

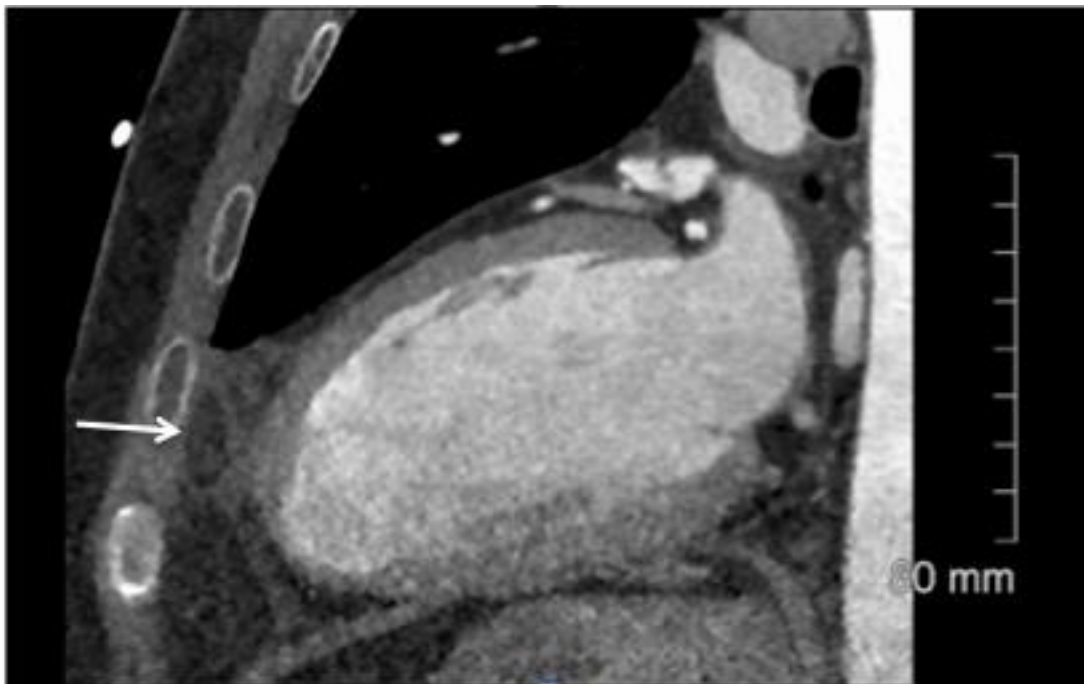


Figure 1. Vertical long axis CT scan shows a well-defined fatty lesion (arrow) with marked surrounding fat stranding.

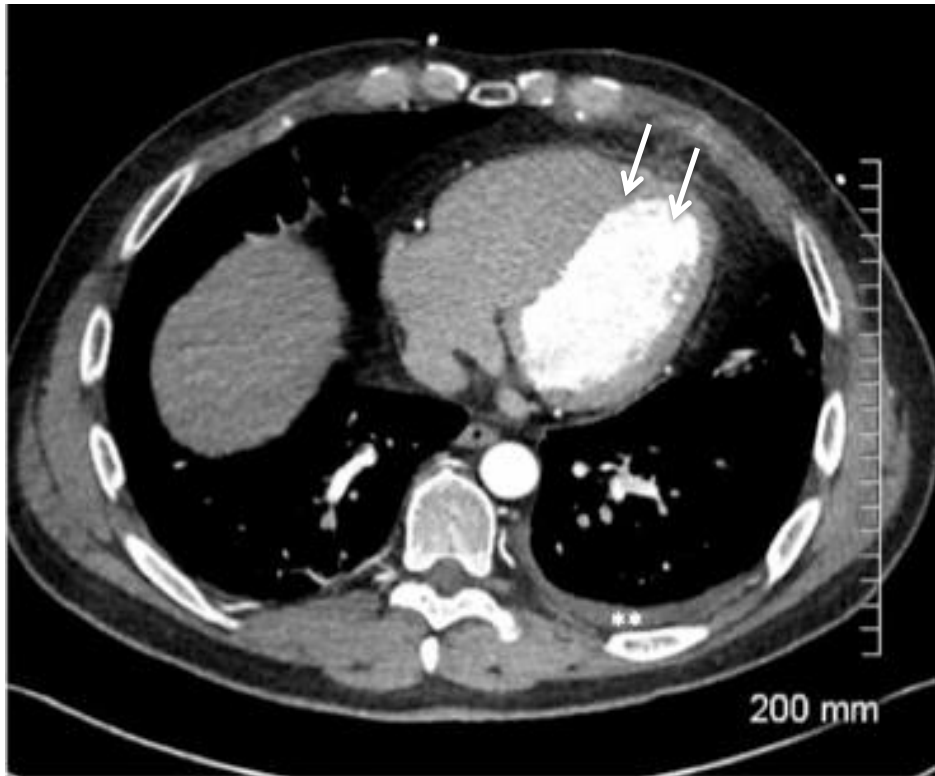

Figure 2. Axial CT scan depicts also left pleural effusion (asterisk) in addition to pericardial changes (arrows).

Discussion

Fatty cardiophrenic angle lesions have a broad differential diagnosis that ranges from benign entities such as diaphragmatic hernia and fat necrosis to malignant entities such as liposarcoma.

Pericardial fat necrosis is a relatively rare entity with no known identifiable cause typically manifesting with acute pleuritic chest pain. The underlying pathologic features are similar to those of fat necrosis in epiploic appendagitis⁴. On CT, it appears as an encapsulated fatty lesion associated with adjacent fat stranding, and occasionally an associated pleural effusion⁵.

Perivascular fat stranding has been described in some patients with significant stenosis, plaque rupture or spontaneous coronary artery dissection warranting close inspection of the underlying coronary arteries³. At echocardiography, pericardial fat necrosis may appear as an ovoid echogenic structure that has a hyperechogenic rim without associated vascularity⁶ however appearances may be normal.

Furthermore, very few publications have reported MRI findings of pericardial fat necrosis. Lee et al. have divided MRI findings according to pathologic stages into acute and chronic. The acute stage is characterized by peripheral rim and the central dot-and-line of low signal intensity T1- and T2-weighted images.

On late gadolinium sequence, at the same stage, peripheral rim enhancement has been described which is likely corresponds to reactive tissue. Progressive fibroblastic proliferation may result in central globular and peripheral rim enhancement in the chronic stage⁷.

Similar to epiploic appendagitis, pericardial fat necrosis requires conservative treatment since both of them are self-limited pathologies.

With increasing numbers of CTCAs being performed in clinical practice, the presence of epicardial fat stranding should alert the radiologist to carefully exclude underlying coronary artery dissection and plaque rupture whilst being aware of pericardial fat necrosis as a benign self-limiting condition, which could potentially be the cause for the patient's acute chest pain.

Declaration of Conflicts of Interest:

The authors have no conflicts of interest to declare.

Corresponding Author:

May Alsharif
Department of Radiology,
St. James's hospital,
Dublin,
Ireland.
E-Mail: May.alsharif@yahoo.com

References:

1. Jackson RC, Clagett OT, McDonald JR. Pericardial fat necrosis: report of three cases. *J Thorac Surg* 1957; 33:723 –729
2. Collet JP, Thiele H, Barbato E, Barthélémy O, Bauersachs J, L. Bhatt D, et al. 2020 ESC Guidelines for the management of acute coronary syndromes in patients presenting without persistent ST-segment elevation. *European heart journal*. 2020.
3. Hedgire S, Baliyan V, Zucker EJ, Bittner DO, Staziaki PV, Takx RA, et al. Perivascular Epicardial Fat Stranding at Coronary CT Angiography: A Marker of Acute Plaque Rupture and Spontaneous Coronary Artery Dissection. *Radiology*. 2018;287(3):808-15.
4. Pineda V, Andreu J, Cáceres J, Merino X, Varona D, Domínguez-Oronoz R. Lesions of the cardiophrenic space: findings at cross-sectional imaging. *Radiographics*. 2007 Jan-Feb;27(1):19-32. doi: 10.1148/rg.271065089. PMID: 17234996.
5. Ataya D, Chowdhry AA, Mohammed TL. Epipericardial fat pad necrosis: computed tomography findings and literature review. *J Thorac Imaging*. 2011;26(4):W140-2.
6. Alomari L, Khushaim A. Diagnosis of Epipericardial Fat Necrosis on multimodality imaging in a pediatric patient: a case report and review of the literature. *Journal of Radiology Case Report*. 2020 May; 14(5): 16–24.
7. Lee HH, Ryu DS, Jung SS, Jung SM, Choi SJ, Shin DH. MRI Findings of Pericardial Fat Necrosis: Case Report. *Korean Journal Radiology*. 2011;12(3):390-394